

# Research Journal of Pharmaceutical, Biological and Chemical Sciences

## Study of Accessory Foramina Transversaria in Cervical Vertebrae and Their Surgical and Morphological Importance.

Gyanaranjan Nayak\*, Biswa Bhusan Mohanty, Pratima Baisakh, Saurjya Ranjan Das,  
Sitansu Kumar Panda, and Prafulla Kumar Chinara.

Department of Anatomy, IMS & SUM Hospital, SOA University, Bhubaneswar, Odisha, 751003

### ABSTRACT

Cervical vertebrae, the smallest of the moveable vertebrae are characterized by the presence of a foramen transversarium in each transverse process. The foramen transversarium of a typical cervical vertebra transmits the second part of the vertebral artery surrounded by a plexus of sympathetic nerves and vertebral veins. Foramina transversaria are known to vary in their number and size which may lead to significant clinical conditions. It may be due to variable course of the vertebral artery which implicates an embryological basis. The accessory foramina transversaria are of importance to radiologists and surgeons operating on the cervical spine. 133 cervical vertebrae available in the Department of Anatomy at IMS and SUM Hospital, Bhubaneswar were macroscopically studied to find variations in the number of foramina transversaria. Out of 133 cervical vertebrae accessory foramina transversaria were found in 8 vertebrae (6%). The accessory foramina transversaria were unilateral in 6 vertebrae (4.5%) and bilateral in 2 vertebrae (1.5%). The unilateral foramina were more common than the bilateral one. The accessory foramina were smaller compared to the regular foramina transversaria.

**Keywords:** Cervical vertebrae, Foramina transversaria, Vertebral artery.

*\*Corresponding author*

## INTRODUCTION

The cervical vertebrae are identified by the presence of a foramen transversarium in each transverse process. The foramen transversarium normally transmits second part of vertebral artery, vertebral vein and sympathetic fibres from the cervicothoracic ganglion (vertebral nerve) [1] except the seventh cervical vertebra which transmits only the vertebral vein. The transverse process has anterior and posterior roots, terminating laterally as tubercles. Both these tubercles are joined by a bar of bone called the costotransverse bar. The foramen transversarium is usually composite in development as it is formed by the fusion of the costal elements to the vertebral body and its true transverse process. The vertebral vessels and nervous plexus are caught between these two parts. So the variation in foramina transversaria may lead to abnormal course of vertebral artery. In such a scenario, the vertebral artery may be compressed, particularly during movements of the head leading to vascular insufficiency. This may manifest as headache and fainting attacks [2]. Compression of the vertebral artery may lead to hearing disturbances as it supplies the internal ear [3].

The anatomical variation of the foramina transversaria is also of paramount importance to neurologists and surgeons performing posterior cervical spine surgeries which may involve instrumentation or screwing in the cervical spine and also to the radiologists for the proper interpretation of X-ray and CT-scan [4]. So the objective of the present study was to find out the incidence of double foramina transversaria in the cervical vertebrae and its morphological and clinical significance.

## MATERIALS AND METHODS

The study included 133 dried human cervical vertebrae available in the Department of Anatomy, IMS and SUM Hospital, Bhubaneswar. Among them there were 76 typical vertebrae and 57 atypical vertebrae. Vertebrae with pathological changes were excluded from the study. The vertebrae were macroscopically studied to find out presence of accessory foramina transversaria. A 24 gauze needle was passed through the accessory foramina to ensure their patency. Vertebrae with accessory foramina transversaria were photographed. The data was compiled and analysed.

## RESULTS

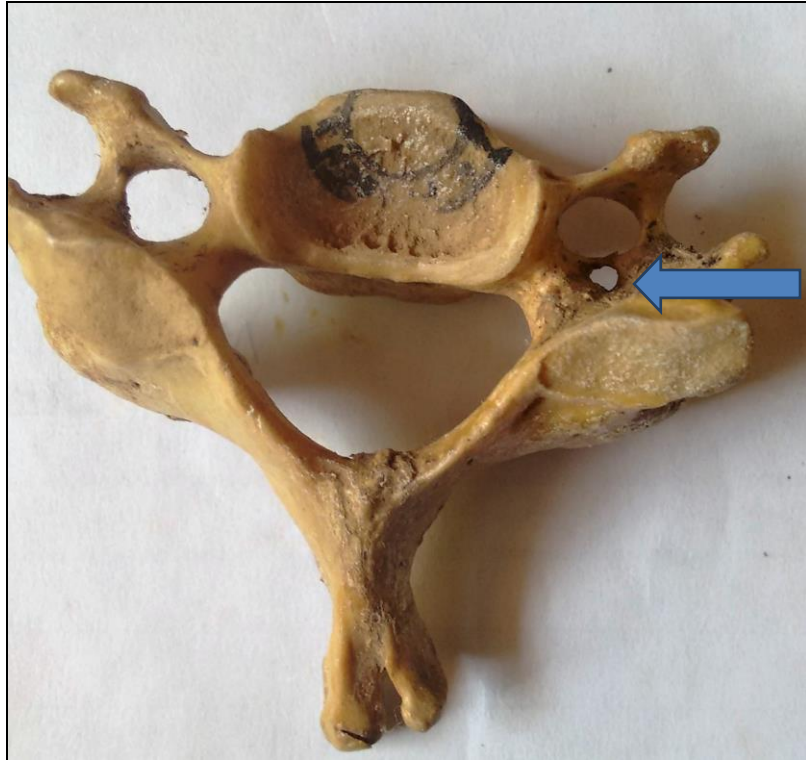Double foramina transversaria were observed in 8 vertebrae. Incidence was calculated to be 6%. Among them the accessory foramina were unilateral in 6 vertebrae(4.5%) and bilateral in 2 vertebrae(1.5%). The accessory foramina were smaller compared to the regular foramina and they were mostly observed in the lower cervical vertebrae(C4,C5,C6 and C7). Table-1 shows the incidence of accessory foramina transversaria in the cervical vertebrae studied. Photograph 1 shows unilateral double foramina transversaria whereas Photograph 2 shows bilateral double foramina transversaria.

**Table-1: Incidence of double foramina transversaria in various cervical vertebrae in our study**

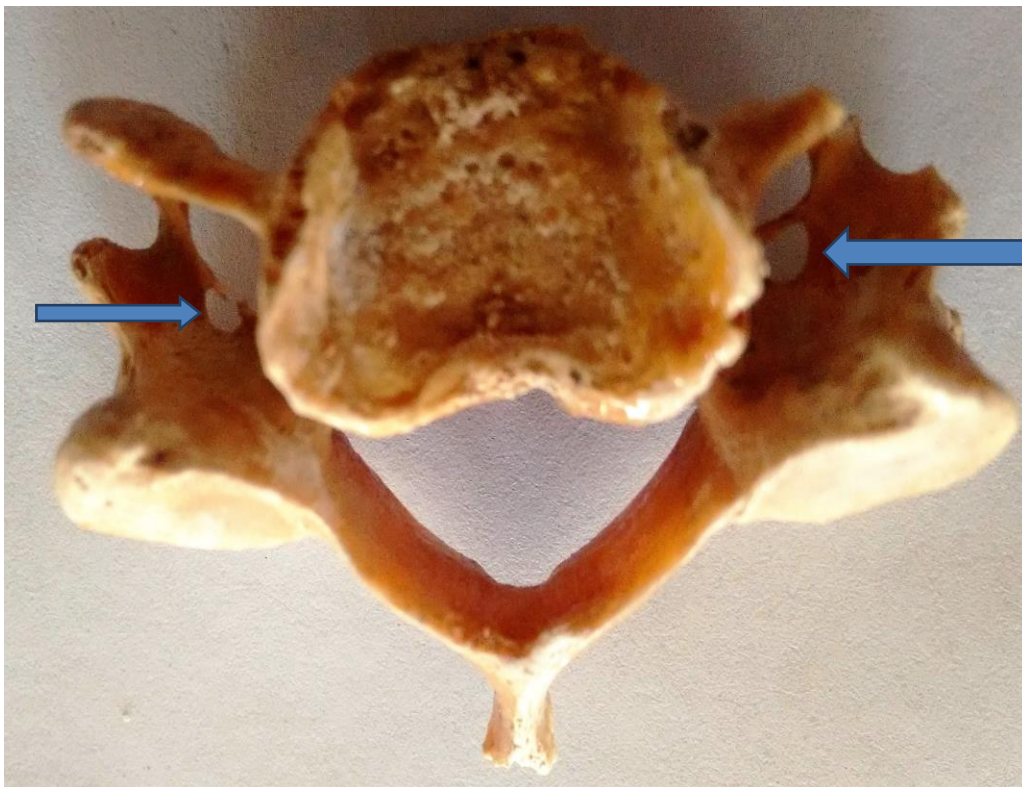
Type of vertebra	Number of vertebra observed	Unilateral double foramina transversaria	Bilateral double foramina transversaria	Total
C3, C4, C5	57	2	1	3
C6	19	3	1	4
C7	19	1		1

## DISCUSSION

The vertebral artery is developed from the fusion of the longitudinal anastomoses that link the cervical intersegmental arteries which arises from the dorsal aorta. These inter segmental arteries regress except for the seventh intersegmental artery which persists and forms the proximal portion of the subclavian artery which gives rise to the vertebral arteries [5]. Sim et al [6] described that persistence of a portion of the primitive dorsal aorta with two intersegmental arteries may give rise to vertebral artery duplication. Since the vertebral vessels are the prime factors in forming the foramina transversaria, we can infer that variation in number and course of the vertebral vessels will lead to variation in number and size of foramina transversaria. In contrast accessory foramina transversaria can be useful in evaluating variant vertebral vessels [7].



**Photograph 1: Cervical vertebra showing unilateral double foramen transversarium**



**Figure 2: Cervical vertebra showing bilateral double foramina transversaria**

In our study double foramina transversaria were found in 6% cases which is comparable to the findings of Taitz et al, 1978 and Nagar et al, 1999. Taitz et al [7] reported the incidence to be 7% in a study

sample of 480 cervical vertebrae whereas Nagar et al [8] reported the Incidence to be 8.6% in a study sample of 1388 cervical vertebrae. However, Das et al [9] have reported an incidence of 1.5% in a study sample of 132 vertebrae. And Kaya et al [4] have reported an incidence of 22.7% in a study sample of 262 vertebrae.

Further we found out that double foramina transversaria were more common in the lower cervical vertebrae.

### CONCLUSION

6% cervical vertebrae showed double foramina transversaria in our study, unilateral accessory foramina transversaria being more common than the bilateral variety. And the accessory foramina were mostly observed in the lower cervical vertebrae. The anatomical variations and morphology of the foramina transversaria is useful to the operating spine surgeons and radiologists in the interpretation of X-ray films and CT-scans. Keeping the vertebral artery intact is highly important during cervical procedures since minor lesions lead to haemorrhage which may be severe and troublesome [10]. Compression of the vertebral artery presents with neurological features. Therefore in any surgical intervention or during diagnostic procedures involving the cervical spine or vertebral artery, these findings should be kept in mind.

### REFERENCES

- [1] Susan Standring, Gray's Anatomy, 40<sup>th</sup> Edition, The anatomical basis of clinical practice, Churchill Livingstone, p-718.
- [2] Caovilla H H, Gananca M M, Munhoz M S, Silva M L: Síndrome Cervical Quadros Clínicos Otoneurológicos Mais Comuns. *Athenue, Sao Paulo*, 2000.3(11),95-100.
- [3] Romanov V A, Miller L G, Gaevyi M D: The effect of the vertebral nerve on circulation in the inner ear (cochlea). *Biull Eksp Biol Med*, 1973, 75:10-12.
- [4] Kaya S, Yilmaz N D, Pusat S, Kural C, Krik A, Izei Y: Double foramen transversarium variation in ancient byzantine cervical vertebrae; Preliminary report of anthropological study. *Turkish Neurosurgery*. 2011, 21(4), 1534-538.
- [5] Mikityansky I: Neuroradiology Case of the Week. Case 334. University of Rochester Medical Center. [www.urmc.rochester.edu/rad/neurocase334.htm](http://www.urmc.rochester.edu/rad/neurocase334.htm).
- [6] Sim E, Vaccaro A R, Berzlanovich A, Thaler H, Ullrich C G: Fenestration of the extracranial vertebral artery: Review of the literature. *Spine*, 2001, 26: 139-142.
- [7] Taitz C, Nathan H, Arensburg B: Anatomical observation of the foramina transversaria. *J. Neurol Neurosurg Psychiatr*, 1978, 41:170-176
- [8] Nagar y, Taitz C, Reich R, What can we make of these fragments? Excavation at "Mamilla" Cave, Byzantine Period, Jerusalem. *Int J Osteoarcheol*, 1999, 9:29-38.
- [9] Das Srijit, Suri R, Kapur V. Double Foramina Transversaria: An Osteological Study with Clinical Implications. *Int Med J*; 2005, 12:311-313
- [10] Riewk: Microscope-assisted anterior decompression and plating techniques for multilevel cervical spondylosis. *Operative Technique in Orthopaedics*, 1988, 8:22-33.